

**PATIENT**

Yogi Gianchetti

**SPECIES**

Feline

**BREED**

DSH

**SEX**

Male Neutered

**AGE**

5 years

**WEIGHT**

9.63lbs

**INTERPRETED BY**

Maggie Machen  
Lamy, DVM  
DACVIM (Cardiology)

**PRESENTING CLINICAL SIGNS**

History: Recheck echo. History perimembraneous VSD, left to right shunting, no left heart enlargement. Previous echo (11/30/21 MML) demonstrated the shunt flow (4.8m/s), normal LA (1.3 cm), normal LV (1.7 cm). Left ventricular remodeling with fibrinous webbing and single, enlarged papillary muscle. Yogi is doing very well at home with no clinical issues. On exam today, no murmur is noted (previously grade II/VI), lungs clear. BP: 120mmHg. On Pimobendan 3.75mg, 1/3 T BID.

**ECHOCARDIOGRAM FINDINGS**

2D, m-mode, color flow and Doppler imaging is available.

**Left ventricle:** The LV diameter is normal with adequate myocardial function. The LV wall thicknesses are normal. A perimembraneous restrictive VSD is identified, although no flow is seen across the lesion; suspect aneurysmal closure. The endocardium appears mildly remodeled. Apical fibrotic webbing is identified with a single enlarged papillary muscle. No obvious obstruction to flow is identified.

**Left atrium:** The left atrium is normal. No obvious spontaneous contrast or thrombi seen.

**Mitral valve:** The mitral valve is thickened, although no obvious stenosis or prolapse seen. No obvious systolic anterior motion is seen. Trace MR.

**Aortic valve/Aorta:** The aortic valve is normal in morphology and mobility. No aortic insufficiency.

**Right ventricle:** Normal right ventricular diameter and morphology indicating no overt evidence of pulmonary arterial hypertension.

**Right atrium:** The right atrium is normal in dimension.

**Tricuspid valve:** The tricuspid valve appears normal with no tricuspid regurgitation.

**Pulmonic valve/Pulmonary artery:** The pulmonic valve is normal in morphology and mobility. No pulmonic insufficiency. Normal RVOT velocity; laminar flow.

**Pericardium/other:** No pericardial or pleural effusion noted. No obvious cardiac masses.

**Heart rhythm:** ECG reveals a sinus rhythm with an average HR of 150bpm.

**2-Dimensional Measurements**

Ao diam (cm)	1.0
LA diam (cm)	1.3
LA:Ao (Swe)	1.3
IVS thickness (cm)	0.40
LVID diastole (cm)	1.6
PW thickness (cm)	0.38
LVID systole (cm)	0.8
FS (%)	50

**Doppler Measurements**

PV Vmax (m/s)	0.77
AoV Vmax (m/s)	NM
MR Vmax (m/s)	NM
TR Vmax (m/s)	NA
TR PG (mmHg)	NA

**IMAGING**

**PERFORMED BY**

Pamela Harrigan,  
RDCS

**HOSPITAL NAME**

Mass Veterinary Services

**REFERRING VET**

Dr. Masloski

**INVOICE**

29929

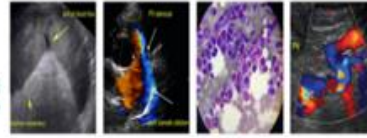
**DATE**

3/29/23

**INTERPRETATION OF THE FINDINGS**

Compared to the prior study, findings are similar. The LV morphology remains highly irregular with webbing; however, no left atrial enlargement has developed. What is unexpected is the previously documented VSD appears to have closed. This is unusual to see, particularly in this age of patient. No additional issues are identified.

Given these findings, no additional medications are indicated. Continue Pimobendan as previously prescribed. Prognosis remains open long-term; however, the changes to the LV are somewhat concerning.



**PATIENT**

Yogi Gianchetti

**SPECIES**

Feline

**BREED**

DSH

**SEX**

Male Neutered

**AGE**

5 years

**WEIGHT**

9.63lbs

**INTERPRETED BY**

Maggie Machen Lamy, DVM  
DACVIM (Cardiology)

**IMAGING PERFORMED BY**

Pamela Harrigan, RDCS

**HOSPITAL NAME**

Mass Veterinary Services

**REFERRING VET**

Dr. Masloski

**INVOICE**

29929

**DATE**

3/29/23

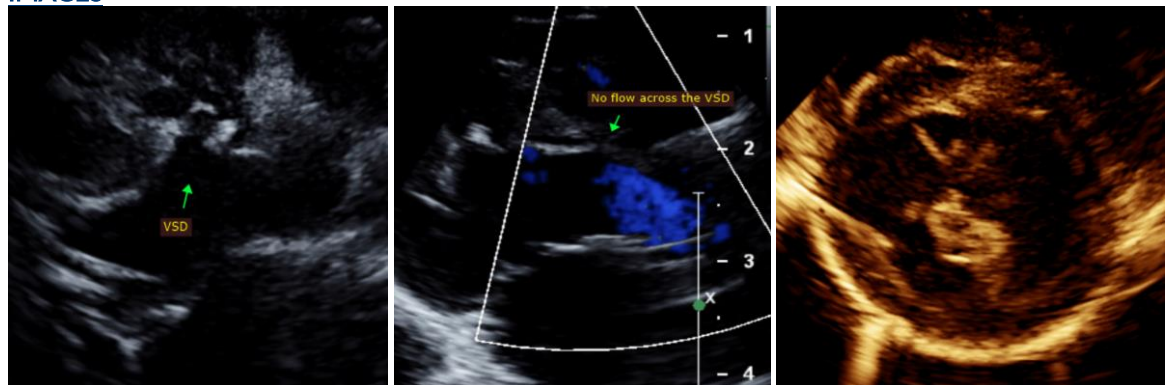
**RECOMMENDATIONS**

- Continue Pimobendan as prescribed.
- Anesthetic risk is considered mild, however judicious IV fluid rates are advised to avoid fluid overload. Additionally, drugs that stimulate heart rate should be avoided unless clinically necessary (glycopyrrolate, atropine). Avoid vasodilators as this may worsen the obstruction. A reasonable protocol includes opioid/benzodiazepine premedication, propofol induction, and isoflurane maintenance. Additionally, steroids should be used with caution on older cats, as even a 'normal' geriatric heart can develop evidence of intolerance and fluid retention.
- Monitor for any clinical evidence of cardiac compromise, including respiratory changes and/or signs of a blood clot event (paralysis, neurologic changes, etc.).

**PLAN**

- Recommend recheck echocardiogram annually, sooner if any clinical issues arise.

**IMAGES**



The information and recommendations provided are based on the images presented by the referring veterinarian. No evaluation can be communicated regarding pathology that was not visible in the image/video clips provided.

Thank you for this referral. This report was generated using transcription software, and minor dictation errors may be present. If the clinical or image interpretation does not parallel your findings or if I can be of any further assistance, please contact me.

Maggie Machen Lamy, DVM  
Diplomate of the American College of Veterinary Internal Medicine (Cardiology)  
info@sonopath.com

Echocardiogram performed by: Pamela Harrigan, RDCS  
Pet Animal Ultrasound Service (4paus.com)